

## COMPARISON OF DIFFERENT LABORATORY METHODS FOR DIAGNOSIS OF *CRYPTOSPORIDIUM*

MOHAMMED ABDUL AZIZ KADIR SUHAIR TARIQ EL YASSIN

College of Medicine, Tikrit.

Received 8/5/2001, Accepted 2/5/2002

### Summary

The present study was carried on to compare several methods for identification of *Cryptosporidium* oocysts sp. which conclude modified acid fast stain, Sheather's flotation solutions, Ritchi formal-ether sedimentation solutions, noval stain and iodine technique. The modified acid-fast stain and its combination with formal – ether technique gave the best demonstration 100%. The most reliable technique for identification of oocysts was formal- ether concentration combination with modified acid fast stain (100%), followed by using modified acid fast stain only (97%), sucrose flotation technique (90%) novel staining technique (85%), formal-ether concentration (84%), and iodine technique (69%) respectively.

### مقارنة الطرق المختبرية المختلفة المستعملة لتشخيص طفيلي داء الابواغ الخبيثة

محمد عبد العزيز قادر      سهير طارق الياسين

كلية الطب - جامعة تكريت ، تكريت - العراق

### الخلاصة

اجريت الدراسة لمقارنة الطرق المختلفة لتشخيص داء الابواغ الخبيثة والتي تتضمن طريقة اللطخة المقاومة للحمض وطريقة تطويف بمحلول شيدر (Sheather's flotation method)، وطريقة الفورمل ايثر وطريقة الترسيب مع اللطخة المقاومة للحمض، وطريقة مسحة الايودين بالاضافة الى الطريقة الحديثة Novel stain. تبين ان اللطخة المقاومة للحمض المحورة ودمجها مع طريقة الفورمل ايثر اعطت فعالية او كفاءة للكشف عن اكياس بيض طفيلي الابواغ الخبيثة وبنسبة 100% لحساسيتها وخصوصيتها، واعقبها طريقة اللطخة المقاومة للحمض المحورة وحدها وبنسبة 90%، وطريقة الصبغة الجديدة بنسبة 85%، وطريقة الفورمل ايثر بنسبة 84% وطريقة صبغة الايودين بنسبة 69%.

## INTRODUCTION

*Cryptosporidium* is a coccidian parasite that usually infects the gastrointestinal tract of human and animal causing intestinal and extra intestinal disorders. This parasite belongs to the phylum Apicomplexa in the suborder Eimeriina that include three families<sup>(1, 2, 3, 4)</sup>.

Numerous methods have been proposed for the diagnosis of *Cryptosporidium* in animals and human beings, based on location of the parasite in the specimen<sup>(5)</sup>. Various staining methods and concentration techniques have been applied to the detection of *Cryptosporidia* having the advantage of being easy to perform for routine diagnosis.

Special techniques can be used for storing stool for several months at 4°C, or it can be used directly<sup>(6)</sup>. As a rule, thin smears of stool are prepared for staining, if necessary diluting solid fecal material 1:5 with water for this purpose<sup>(7)</sup>. The prepared smear is fixed in absolute alcohol and allowed to dry; any suitable staining procedure can then be applied<sup>(8)</sup>.

The numerous staining procedures are listed in the Table 1 below. Giemsa staining was the first to be used<sup>(9)</sup>, but a recent study comparing fifteen ways of detecting oocysts<sup>(10)</sup> showed that the best results are obtained with acid-fast staining methods, notably Ziehl-Nelson's techniques as modified by Henriksen<sup>(11)</sup>. However, numerous authors advocate the auramine technique as more sensitive and more specific for cryptosporidial oocysts<sup>(12, 13)</sup>.

The study was planned to show the most effective laboratory method for diagnosis of *Cryptosporidium*.

## MATERIALS & METHODS

The total number of population involved in this study was 455 patients, including 300 males and 155 females classified in to two groups; 105 immunocompromised patient and 350 immunocompetent (control group).

Age group was below one year old -15 years, 16 years- 30 years, over 31 years old.

Single stool sample was obtained from each patient in a tightly covered wide mouth plastic disposable container. These were labeled with sample numbers, date and name of patient.

Several methods had been used in the study for the identification of the parasite such as Modified acid fast stain by Hinriksen & Pohhien<sup>(14)</sup>, Iodine stain

(Lugols iodine)<sup>(15)</sup>, Sheather's flotation solution<sup>(5)</sup>, Ritchi formal - ether sedimentation solution<sup>(15)</sup> and the Novel stain that been used for the first time in Iraq. is a modification of Heini's method .that usually used 10 gm of basic fuchsin in 100 ml of 95% ethanol by using a phase contrast microscope for diagnosis, which in our modification the volume of stain dissolved in ethanol was changed from 10 gm to 7 gm and using the available light microscope instead of phase contrast microscope.

## RESULTS

An oocyst structure appears under the light microscope on the power X100 oil immersion as rounded-ovoid bodies with a distinct color in each stain. Sizes of oocysts obtained from immunocompromised patients ranged from 4.5-5.3  $\mu$ m, while others obtained from control groups were 4.2-5.5  $\mu$ m.

In modified acid fast stain, the oocysts were red-bright rounded bodies, surrounded by green-blue background (Fig.1). About 96% of cryptosporidiosis cases detected positive by this method.

In technique involving iodine, the oocysts appear bright yellow rounded bodies, surrounded by bright yellow translucent walls, and the background was dark yellow grey. (Fig.2). About 69% of cryptosporidiosis cases detected positive by this method.

When preparation was stained with the novel technique. *Cryptosporidium* oocysts appear as dark red ovoid-rounded bodies with a distinct wall, the background was bright red. In this method all protozoa cysts appear in the same color but with different shapes and sizes. (Fig, 3). About 85% of positive cases were detected by this method.

Sucrose flotation technique was used for fecal specimen concentration. This technique needed some experience and focussing for well observation of *Cryptosporidium* oocyst. The oocysts appear as round-ovoid bodies containing bright granules, and clearly visible faint intrinsic color (Fig. 4). About 90% of cryptosporidiosis cases detected positive by this method.

Other results obtained by using Ritchi formal-ether concentration method were excellent for giving positive diagnosis. *Cryptosporidium* oocyst appears as translucent bodies that cannot diagnosed directly, due to autolysis. About 84% of cryptosporidiosis cases detected positive by this method.

Both concentration methods were almost equal in giving specific diagnosis for *Cryptosporidium* oocysts.

The technique concerned with formal-ether concentration combined with modified acid fast stain, were excellent for giving 100% rate of diagnosis for

*Cryptosporidium* oocysts. This method provides a good chance for oocysts to appear in this smear comparing with using the modified acid fast only is high (Fig. 5), about 96% of positive cases were detected by this method.

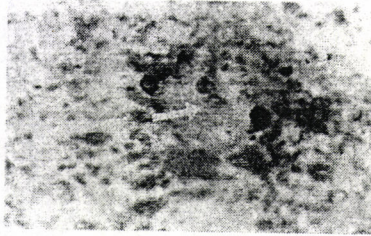


Fig. 1: *Cryptosporidium* oocyst by using modified acid fast stain X100.




Fig. 2: *Cryptosporidium* oocyst by using iodine stain X100.

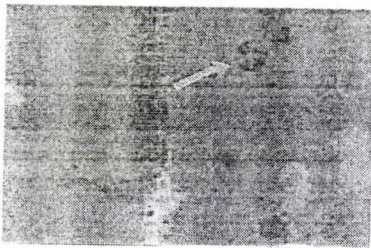


Fig. 3: *Cryptosporidium* oocyst by using novel method X100.

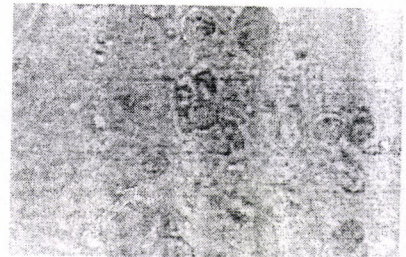

Fig. 4: *Cryptosporidium* oocyst by using flotation method X100.

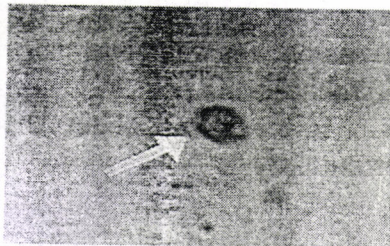


Fig. 5: *Cryptosporidium* oocyst recovered by using sedimentation method & modified acid fast stain X100.

## DISCUSSION

This study proved that out of 3 staining methods used to identify oocysts in the stool sample (modified acid fast stain, iodine and the Novel staining). The modified acid fast stain was found to be more efficient for the first observation.

More over the slide can be kept, this agreed with the results obtained by<sup>(14, 16, 17)</sup>. This method confirms its importance for clinical diagnosis for the causes of diarrhea. It clearly detected the other pathogens as yeast and bacteria that take green color other than red-pink. Low number of oocysts found in the specimen might lead to the 3% misdiagnosis. Iodine stain smear proved to need some experience and good focusing in order to give best results. One of its disadvantages is the ability to give misdiagnosis with other yeasts (*Candida*) or other organisms with the same size and shape of *Cryptosporidium* oocyst. The slide must be directly examined, and positive smears can not be kept for more than 10-15 mints, this method is still effective in 65% of cases, need no time, iodine solution can be found in any laboratory and its not expensive. Map & Soave<sup>(18)</sup>, and Fleck & Moody<sup>(15)</sup>, confirmed this result.

Novel technique was used for staining to evaluate the number of positive cases that could be diagnosed by using simple single stain in routine laboratory works. *Cryptosporidium* oocyst appears in a size of 4 - 5.1 Mm. Oocyst appears refringent dark red bodies against bright background. This method proved to give expectable results between Modified acid fast and iodine stain by using diluted carbol fuchsin and light microscope.

The oocysts can be well differentiated from other parasites. Casemore used Heini's method that gave the same result<sup>(5)</sup>. This method can simply provide; a new quick, short time and in expensive properties.

All these which are important to any laboratory, can favorite the usage of this novel method in the diagnosis of *Cryptosporidium* oocyst than the iodine stain that need much more experience and the modified acid fast smear that need two stains, ethanol and toxic  $H_2SO_4$ . The advantages of this Novel method can be summarized by:

Decreasing the amount of stain used, and the ability to diagnose by using light microscope, which is much more cheaper than using phase contrast microscope.

This method is excellent for using when there are a high number of suspected specimens, which must be diagnosed for the cause of diarrhea in a very short time without expensive evaluation. These factors are always found among general laboratories in hospitals and healthy units in villages specially those far from towns with factors that favorite the infection. No documented report till today used the new method as far as we know.

The results obtained from stool samples examination, proved that both formal-ether sedimentation and sucrose flotation method for concentration of oocyst gave almost equal results. The low number of oocysts that were found in some examined specimens might be due to; number of oocysts found in the

specimen, loss of oocysts during the preparing of methods, oocysts lysis specially in flotation method after one hour of preparation and misdiagnosis of fecal debris that have the same size and shape of *Cryptosporidium*. These results were shared with the results obtained with that reported Garcia *et al.*<sup>(19)</sup>.

Modified acid-fast stain was used for smears obtained from formal-ether sedimentation method; these were proved to be the most effective diagnostic method for *Cryptosporidium* oocyst identification. Even with low number of oocyst, it appears in a good number for diagnosis with modified acid fast. These results are in agreement with many other studies<sup>(20, 21, 22)</sup>.

Examination of one specimen is generally appropriate for the diagnosis of cryptosporidiosis in hospitalized patients presenting with diarrhea and examination of second specimen may be appropriate if the first specimen was negative and there is a clinical index of suspicion<sup>(23)</sup>.

## REFERENCES

1. Soave R. and Armstrong D. (1986) *Cryptosporidium* and cryptosporidiosis. J. Infec. Dis, 8 1021-23.
2. Tzipori S. (1998) Cryptosporidiosis: laboratory investigations and chemotherapy. Adv. Parasitol, 40: 187-94.
3. Miller R.; Holmberg R. and Clusen C. (1983) Life-threatening diarrhea caused by *Cryptosporidium* in child undergoing therapy for acute leukemia. J. Pediatr., 103:256-59.
4. Mackenzie W. R.; Hoxie N. J.; Proctor ME; Grades M. S.; Blaire K.A.; and Peterson D.F.(1994)A massive outbreak in Milwaukee of *Cryptosporidium* infection transmitted through the public water supply. N.Eng.J.Med,331,161-67.
5. Casemore D.P.(1989) Human cryptosporidiosis, Recent advance in infection. 3: 209-236.
6. Moon H. W. & Bemrick W. J. (1981) Fecal transmission of calf cryptosporidiosis between calves and pigs. Vet. Pathol., 18: 248-255.
7. Heinemann D.(1987) Medical parasitology. In: Jawitz E., MeinikJ. L., Adelberg E. A.(Eds.) Review of Medical Microbiology, 17 Edition, Washington Appleton & Long Co. 553.
8. Bennson A. S.(1995) Control of Communicable Diseases Manual. 16 edition Washington, American Public Health. 121.
9. Pavlasek I. Nikitin V. F. (1984 ) [*Eimeria* in calves on industrial farms]. Veterinariya, Moscow; 5 : 44-45.