

**STUDIES OF NOCARDIOSIS IN CATTLE**  
**1 – ISOLATION OF NORCARIDA ASTEROIDES**  
**FROM MASTITIS IN CATTLE**

**M.J. Alwan<sup>1</sup>, A.S. Al-Abaidi<sup>2</sup> and S.Sh.Barhoom<sup>3</sup>**

1. Dept. Vet. Path. 2. Dept. Microbiology.  
3. Dept. Med. Theraps.  
Coll. Vet. Med., Univ. Baghdad, Iraq.

**SUMMARY**

A six months survey (2-8/1994) was carried out to determine norcardial mastitis in cattle in certain dairy herds. A total 126 milk samples collected from mastitic cows and milk tank. Of which 10 from Al-Khalis station, 15 from Al-Wahda station, 6 from White Good village, 90 from Al-Dejaila station and 5 from Milk tank. Examination of the samples result in isolation of Nocardia asteroides from Al-Dejaila station.

The results explained that 25 animals were positive for norcardial infection with prevalence of 20.8 % of these 25 cases, 5 cases, in pure cultural and 20 cases, mixed with other organisms. Bacteriological examination of milk tank also resulted in positive for norcardial isolates.

Metastasis to the lung and supramammary lymph node was demonstrated. The results also explained that norcardial isolates from mastitic cows were more virulent to guinea pigs, and this study revealed that norcardial infection are not rare in cattle.

**INTRODUCTION**

Nocardiosis is an important disease of man and animals (1,2). It caused by the genus of *Norcarida* which belong to the family Actinomycetaceae. The most common pathogen of this

organism is N.asteroides (3). The norcardia was important and probably a common pathogen causing disease in demonstrated cattle throughout the world (4,5).

Bovine norcardiosis is commonly reported as a mastitis, skin farcy and pulmonary disease (6). Bovine mastitis caused by N.asteroides was first reported in Australia in 1954 by Munch-Petersen (7). This disease manifested as an acute, subacute or chronic form which accompanied by extensive granulomatous lesions in the udder. Affected animals may show a systemic reaction with high fever depression, and anorexia (8). Fibrosis of the affected udder was seen in chronic form as well as sinus tract may be developed to the exterior (9). The animals do not respond to antibiotic therapy and in the severe progressive cases, encapsulated abscesses in the parenchyma of the udder may result (10). Secondary dissemination of the infection may occur throughout the blood and lymph stream.

Many workers succeeded in isolating N.asteroides from mastitic cows. In 1957, Pier et al., (10) isolated this organism from milk of 28 out of 157 cows in dairy herd in California. However, this disease was reported in Canada (12) and USA (13). In Newzealand, 34 cases of norcardial infection have been reported between 1976-1978, 26 cases of them consisted of mastitis in cattle (14). Salman et al. (15) reported that among 116 cows, 8 were infected with N.asteroides.

In Iraq, a single case of norcardial mastitis and skin farcy were reported by Al-Bassam et al. (16) and Al-Jashimmy (17).

The purpose of this study is to describe the prevalence of N.asteroides in dairy herds through isolating the organisms as well as the clinical signs will be investigated in the affected cattle.

## MATERIALS AND METHODS

The study was carried out on cattle at different localities (Table.1). Five mastitic cows were isolated and slaughtered. The udder and internal organs were examined. Specimens from affected tissues (Pus, Milk, Tissue) were collected aseptically for bacteriological examination.

### **Bacteriological examination:**

Isolation and identification of the causative agents was performed as the follows:

Direct smears were made from pus, milk samples and were stained by Gram and acid - fast stains.

Each sample was cultural onto brain heart infusion agar containing 7 % sheep RBCs, MacConkeys agar and mannitol salt agar. Incubated at 37 °C for 3 days and checked daily for norcardial colonies. These samples were used after 2-4 hours of collection.

Suspected colonies were subjected to Gram's and acid-fast stains followed by some biochemical tests (Table.2), which done according to Collins and Anne (18).

### **Animal Inoculations:**

Pathogenicity of the isolates for guinea pigs was determined, using sterile saline suspensions from 3 days old colonies on brain heart infusion agar. A dose of  $1 \times 10^9$  organism/mL was inoculated intrapulmonary into 5 guinea pigs. Thermal resistance of the isolated organisms was checked by incubating the plates at 50 °C for 2-3 days.

## RESULTS

### Cultural Identification:

In all examined herds, infection of the mammary glands with certain organisms such as Candida species, Streptococci, Staphylococci, E. coli, Pseudomonas, Klebsiella, Bacillus species, were culturally recorded. N.asteroides were there, in pure culture or in combination with other organism was detectable in the dairy herd of Al-Dejaili station (Table 1). This organism was isolated from 25 of 90 mastitic cows as well as from milk tank (Table 2). This organism also isolated from lung and supramammary lymph nodes of mastitic cows. N.asteroides was isolated in pure culture from 5 cases and in combination with other organisms from 20 cases.

Colonies of N.asteroides were seen on Brain heart infusion agar after 72 hours of aerobic incubation at 37 °C. This colonies are opaque, chalky whitish, firmly adherent to the medium and not haemolytic (Fig.1). Microscopic examination of the colonies showed a filamentous structure at their margined.

After 72 hours, yellowish - orange color was detected, waxy pellicle was also seen in broth culture after 48 hours of incubation. Microscopically, the organisms appear Gram positive branched filament less than 1 mm in diameter which fragmented into bacillary and coccoid forms. Such organisms were partially acid fast stained. Some beaded appearance due to irregular staining. These organisms grow within 2-3 days on blood agar which had been incubated at 50 °C. Growth was not obtained on MacConkey agar at 37 °C.

Table 1 shows results of the biochemical tests of the isolates. The isolates produced neither acid nor gas from

mannitol, sucrose, glucose, and fructose. They reduced nitrate to nitrite and produced urease and they hydrolyzed aesculin.

The isolates killed guinea pigs within 5-6 days after inoculation. N.asteroides was isolated from all internal organs.

### **Clinical Signs:**

Case history of the animals which yielding N.asteroides revealed sudden onset of the disease which closely followed parturition. The clinical case involved first lactation heifer and repeated lactating cows. Acute cases were characterized by fever (40-41 °C), depression, anorexia and cessation of the milk flow. Mammary secretion from infected glands being viscid or watery and contained white-yellow flakes or granules and blood clots may be present which gave tomato-soup like appearance to the milk.

The affected udders were swollen and painful. In chronic form with the udder was enlarged and firm with fibrosis and palpable nodular lesions, some of which rupture and forms draining sinus tracts which exuded whitish exudate to the exterior (Fig. 2). Coughing, loss of the body weight and condition were also seen (Fig. 3). The affected udders were lost its symmetry and and function as well as marker decrease in their size. One or more quarter of the udder may be involved. In most cases (18 cases) the lesions were mainly seen in dorso-posterior regions of the right rear quarter of the udder and in the other cases (5 cases) diffuse fibrosis and sinus tract were seen in both right and left rear quarters. Affected frontal quarters were seen in two cases.

## DISCUSSION

The results showed that of 121 mastitic cows, 25 shaded N.asteroides (20.8 %) in their milk samples. Such high incidence of isolation was also reported by Argents et al. (19) who found in six dairy herds. A total number of 227 cows, 41 showed acute mastitis due to N.asteroides, also Tarable et al., (20) were found, that of a total 25 milking cows, 22 cows (84 %) were positive to N.asteroides. Testi et al. (21) reported that of 1956 cows from various districts in Somalia, and from slaughtered cows at Magadischo abattoir, 14 (0.7 %) and 12 (1.2 %) respectively had gross lesions of N.asteroides.

This disease induced economic problems in Al-Dejaila station due to drop in milk production in addition most of the infected animals were culled or discarded from dairy herds because of their poor condition and non-response to antibiotic treatment. Mastitis in cattle caused by N.asteroides has been identified as a problem of economic significance in certain dairy herds (22), because management and control measures are not successful when its diagnosis and specific treatment are delayed in the course of infection (23).

High percentage of norcardial isolates observed in this study, indicates that Norcardiosis is not rare in dairy herds in Iraq, in addition little attention has been received to this disease.

The isolation of N.asteroides alone from 5 cases is a strong evidence for it is being an important cause of bovine mastitis. Some workers isolated this organism from mastitic cows either in pure or in combination with other organisms (24).

The reason for the appearance of such outbreak as well as infected first lactating heifers might be attributed to

contamination of milking machine, improper hygiene of dairy herd station. Pier et al. (8) considered this organism as opportunistic pathogens and mammary gland infections were associated with poor hygiene as well as certain predisposing factors. Norcardial species are normal inhabitants of the soil and cattle are very susceptible to infection. It is very likely that dairies sporadically have individual cows that develop norcardial induced mastitis and these individual cases might remain unrecognized or misdiagnosed due to this organism is not readily isolated or identified by the normal diagnostic procedures used in mastitic laboratories. (4).

The initial infection with N.asteroides might occur during dry period where a focus of infection may remain clinically unrecognized until at parturition as the cow begins to lactation and the udder full with milk, the norcardial foci probably become disrupted and the organism spreads through the lactiferous tree resulting in massive infection and development of clinical signs. However, once *Norcardia* become established within a herd, it tends to spread from one infected cow to another by either multiple used syringes, needles, lack of appropriate use of disinfectants or use of contaminated drugs in udders infusion or by inadequate dairy herd management during milking procedures (25).

The isolation of N.asteroides from milk tank in the present study might be due to subclinical infection of the udder by this organisms or due to low level of hygiene during milking. Shigida ( ) and Mamoun (24) revealed that cows infected with N.asteroides showed no signs of infection and the milk from these animals appeared normal.

The distribution of the organisms in the internal organs indicated that the infection is metastasis to these organs via lymphatic and hematogenous routes. The disease occurs as

acute norcardial mastitis, subsequent pulmonary involvement resulting in chronic pneumonia and the animals may lose their weight and become emaciated, then it is culled due to unfavorable prognosis (23).

The clinical signs which are seen in cattle naturally infected with N.asteroides are similar to those previously reported by Pier et al. (25) who demonstrated that N.asteroides as the etiologic agent of a severe and persistent mammary infection of cattle in 7 dairy herds in California and 3 in Hawaii.

**Table 1 : Norcardial isolation from mastitic cattle.**

Source of milk samples	Number of the samples	Positive
Al-Khalis Station	10	-
Al-Wahda Station	15	-
White Gold Village	6	-
Al-Dujaila Station	90	25
Milk Tank	5	5
Total	126	30



**Table 2 : Some Biochemical and Physiological Characteristic on N.asteroides isolated from mastitic samples.**

Gram stain	+	Hemolysis	-
Fermentation of mannitols	-	Sucrose	-
Acid Fast stains	Partial	Fructose	-
Growth at 50 °C	+	Urease	-
Gelatin Liquefaction	-	Glucose	-
Guinea Pig Inoculation	Died 5 days	Aesculin	+
Nitrate Reduction	+		




Fig. 1 : Showing white, chalky, firmly adherent colonies of N.asteroides on blood agar after 3 days of incubated at 37 °C.

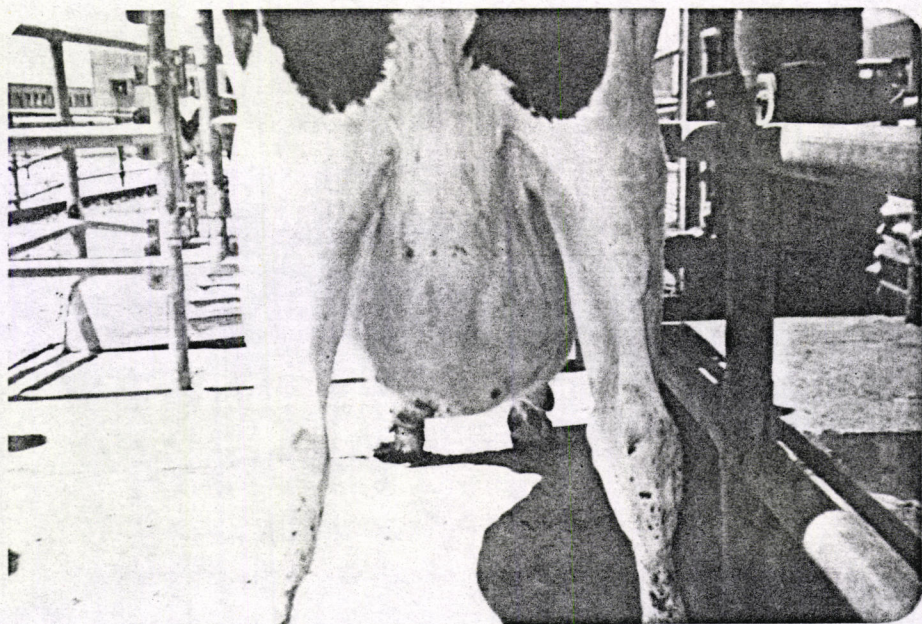

Fig. 2 : Mammary gland of cattle infected with Nocardia asteroides showing draining sinus tract.

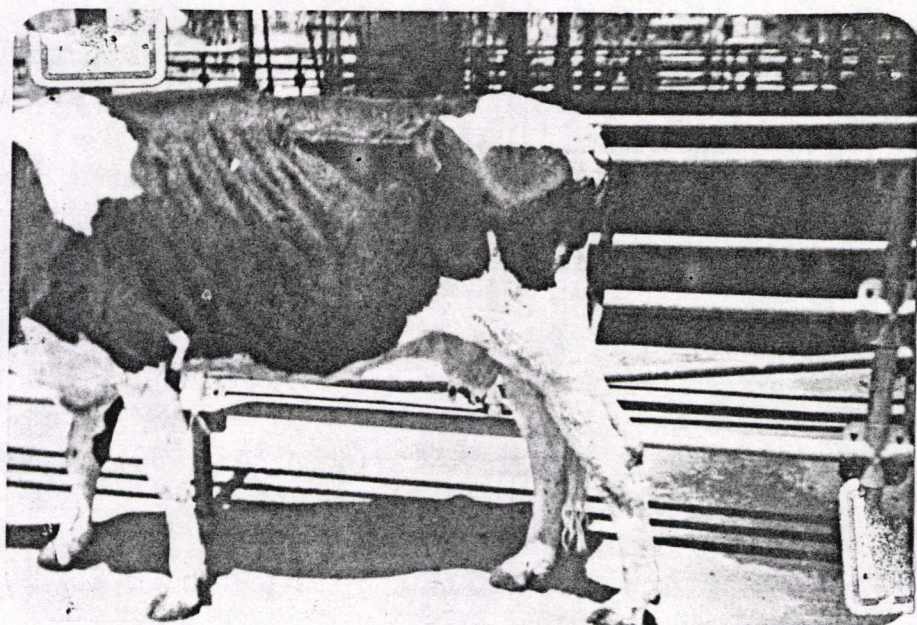


Fig. 3 : Showing emaciated animal with fibrotic udder.

### REFERENCES

1. Pier, A.C. (1962). Nocardiosis of Animals. Proc. cu. S. Livestock. San. A 66 : 409-416.
2. Murray, J.F., Finegold, S.M., Froman, S. and Will, D.W. (1961). The changing spectrum of N.asteroides. Am. Rev. Res. Dis. 83 : 315-330.
3. Merchart, J.A. and Packer, R.P. (1967). Veterinary, Bacteriology and Virology. 7<sup>th</sup> ed. Lawastal University Press. Ames. Lawa. P. 479-482.
4. Bushnell, R.B., Pier, A.C., Fichner, K.E., Beaman, B.L., Boos, H.A. and Salmon, M.D. (1979). Clinical and Diagnostic aspects of herd problems with Nocardial and nycobacterial mastitis. An. A. Vet. Lab. Diag. 22 : 1-12.
5. Pier, A.C., Gray, P.M. and Fossatti, M.J. (1958). Nocardia asteroides. A newly recognized pathogen of the mastitis complex. Am. J. Vet. Res. 19 : 319-331.
6. Francis, W.C., William, K. and Libero, A. (1980). A colour atlas and textbook of the histopathology mycotic disease. Wolse, Medical publication, Ltd.
7. Much-Petersen (1954). Actinomyces (Nocardia) Sp. from bovine udder infection. Aust. Vet. J. 30 : 297-300.
8. Pier, A.C., Mejia, M.J. and Willer, E.H. (1961). Nocardia asteriodes as a mammary pathogen of cattle. I. The disease in cattle and the comparative virulence of 5 isolates. Am. J. Vet. Res. 22 : 502-517.
9. Awad, E.I. (1961). Nocardiosis of the bovine udder and testis. Vet. rec. 72 : 341-342.
10. Pier, A.C., Gray, P.M., and Fossattia, M.J. (1957). Nocardia infection of bovine mammary gland. A preliminary report. J. A. Vet. Med. Ass. 131 : 327-328.

11. Eales, J.D., Leaver, D.D., Swan, J. and Wellington, N.A.M. (1964). Bovine mastitis caused by Nocardia asteroides. Aust. Vet. j. 40 : 321-324.
12. Barum, D.A. and Fuller, P.S. (1956). A report on the isolation of two species of nocardia from bovine mastitis. Coun. St. Hyaciath. Guebec. Canada. Oct.
13. Jungerman, P. (1858). Fungus mastitis. A case report. Vet. Med. 53 : 53-54.
14. Valerie, A.O. (1979). Nocardial infection of animals in Newzealand. 1976-1978. N.Z. Vet. J. 27 : 159-165.
15. Salman, M.D., Bushuell, R.B., and Pier, A.C. (1982). Determination of sensitivity and specificity of the Nocardia asteroides, skin test for detection of bovine mammary infection caused by Nocardia caviae. Am. J. Vet. Res. 43 : 332-335.
16. Al-Bassam, L.S., Kastand, J.D. and Karmalapur, P.N. (1989). Nocardia asteroides as a causative agent of mastitis in dairy cattle in Iraq. Ind. Vet. J. 66 : 10-11.
17. Al-Jashumy, K.A. Muhammed. (1993). Study of skin lesions in some cutaneous affections of cattles in Baghdad province. M.Sc. thesis, University of Baghdad.
18. Collins, C.H. and Anne, H.C. (1988). Presumptive identification of Nocardia in a clinical laboratory. J. Appl. Bact. 65 : 55-59.
19. Argents, R.J., Alemine, H.M., Mencey, L.M. and Lorant, J.M. (1983). Bovine mastitis caused by Nocardia investigation and description of the disease in II infected herds. Point. Veterinaire. 14 : 1-12.
20. Tarable, H.D. Zurbruggen, V.R. Canavesio, C.A. Vitulich, L.F. Calvinho (1993) Nocardia asteroides mastitis in a small argentiniaa herd. Vet. Rec. 132 : 303-303.

21. Testis, B.B. and Mahmoud, H.M. (1982). Nocardia infection of Zebu and cattle. Bulletin, Scientific, della focalta dizotecniae, Veterinaria, Universita Nazionale, Somalia. 3 : 101-114.
22. Blood, D.C., Henderson, J.A. and Radostots, O.M. (1989). Veterinary medicine. 15<sup>th</sup> ed., Balliere, Tindall and cassell.
23. Osiyme, S.T., Okewole, P.A., Dawal, B. and Alli, B.R. (1985). Nocardiosis in a frisenian cow. Bull. Anim. Hith. Prod. Afr. 33 : 23-24.
24. Shigidi, M.T.A. and Mamoun, I.E. (1981). Isolation of Nocardia asteroides from cattle with mastitis in the Sudan. Bull. Anim. Hith. Prod. Afr. 29 : 275-278.
25. Pier, A.C., Willers, E.H. and Mejia, M.J. (1961). Nocardia asteroides as a mammary pathogen of cattle. I. The sources of Nocardia in infection and experimental reproduction of the disease. Vet. Res. 23 : 698-703.

دراسات حول حول داء النوكارديا في الأبقار ١ - عزل جرثومة  
NORCARDIA ASTEROIDES من حالات التهاب الضرع في  
الأبقار

(١) محمد جويد عنوان (٢) عامر العبيدي و (٣) سلامة برهوم  
(١) فرع الأمراض (٢) فرع الأحياء المجهرية و (٣) فرع الطب  
والعلاج

الخلاصة

أجري مسح للفترة الواقعة من شباط إلى آب ١٩٩٤ لمعرفة حالات  
التهاب الضرع التي تسببها جراثيم N.asteroides في بعض محطات الأبقار  
وتجمعاتها حيث تم جمع ١٢٦ عينة حليب من حالات التهاب الضرع في الأبقار  
وخزان الحليب كالآتي: ١٠ عينات من محطة أبقار الخالص ، ١٥ عينة من  
محطة أبقار الوحدة ، ٦ عينات من قرية الذهب الأبيض ، ٩٠ عينة من محطة  
أبقار الدجيلية وخمس عينات من خزان الحليب التابع لمحطة أبقار الدجيلية.  
أظهرت نتائج فحص العينات عزل جراثيم N.asteroides من محطة  
أبقار الدجيلية وخزان الحليب حيث توضح النتائج ان ٢٥ حيوانا كانت ايجابية  
للأصابة بجراثيم N.asteroides بنسبة ٢٠,٨ % . تم عزل الجراثيم في ٥  
حالات بصورة نقطية و ٢٠ حالة كانت هناك اصابة مختلطة مع جراثيم أخرى  
وكذلك تم عزل جراثيم N.asteroides من خزان الحليب.  
لقد تم ملاحظة انتشار المرض إلى الرثة والغدة اللمفاوية الضرعية وان  
العزولات كانت أكثر ضراوة لخنازير غينيا. تظهر هذه الدراسة ان الإصابة  
بجراثيم النوكارديا ليست نادرة الحدوث في الأبقار.